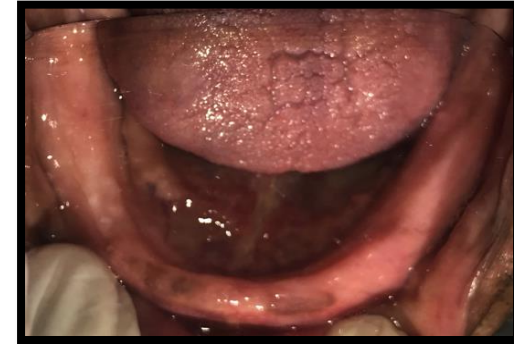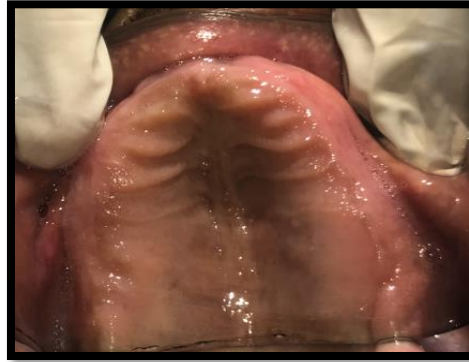
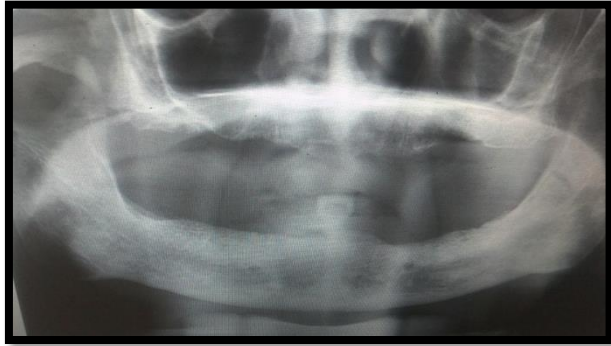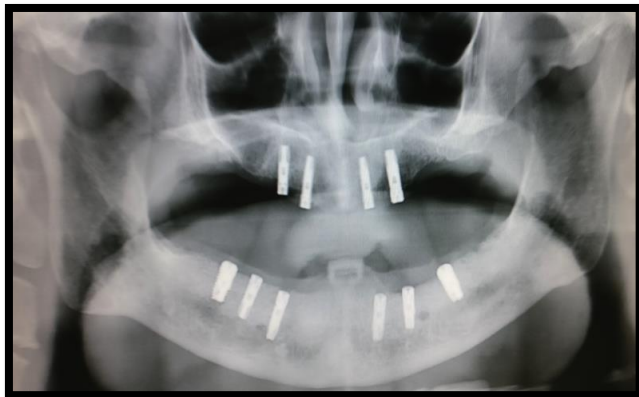


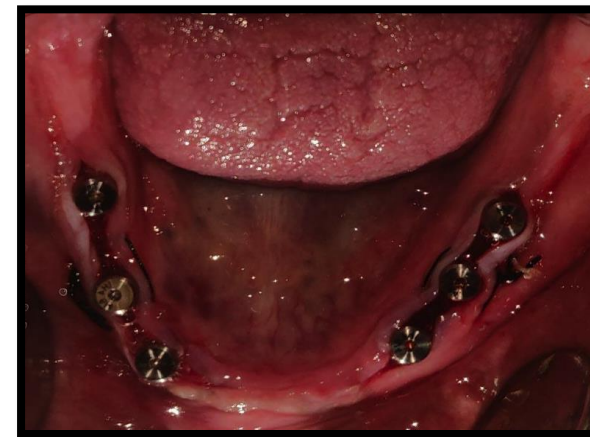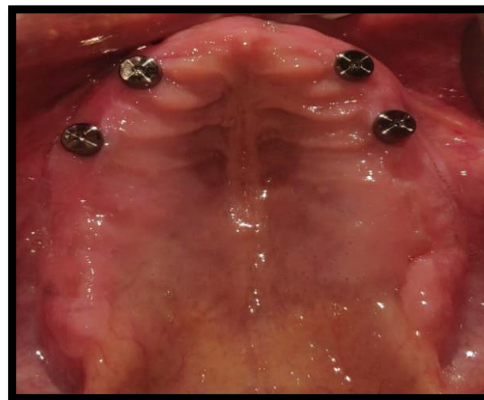
# CASE 3- FULL MOUTH REHABILITATION WITH IMPLANT SUPPORTED OVERDENTURE AND FIXED PROSTHESIS



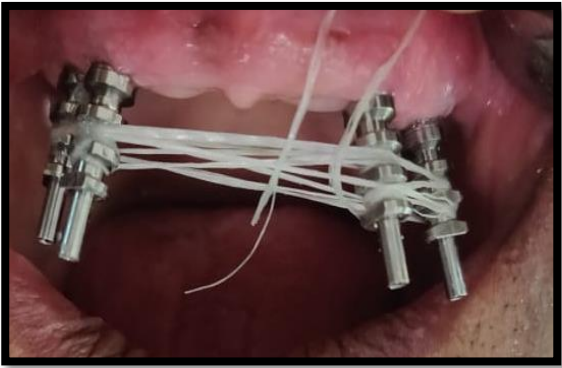
PRE- OPERATIVE OPG AND INTRAORAL PHOTOGRAPHS



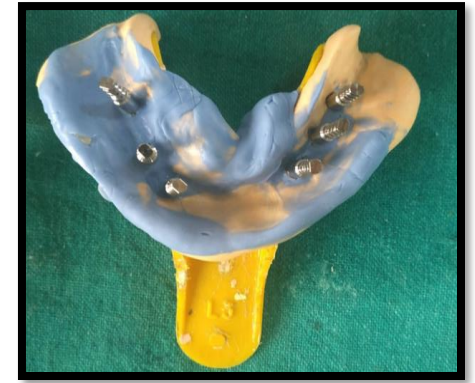
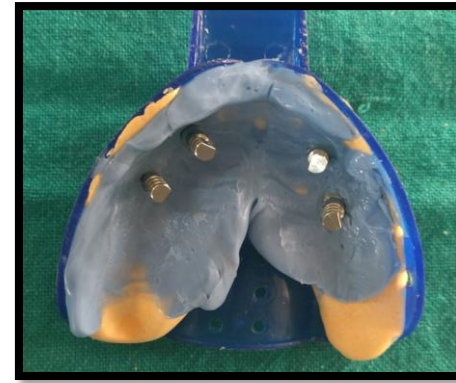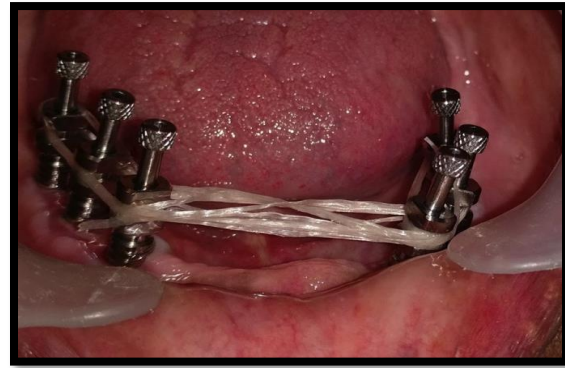POSTOPERATIVE OPG WITH  
IMPLANT PLACED



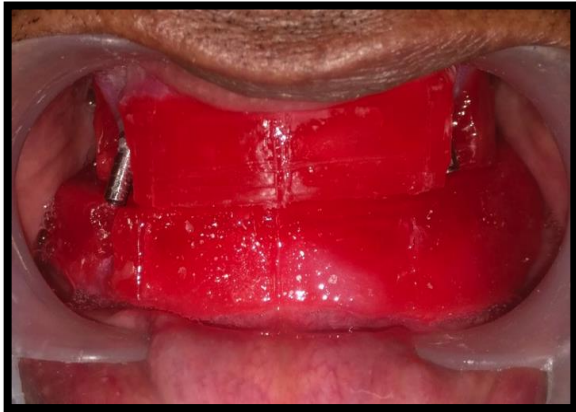HEALING ABUTMENT PLACED



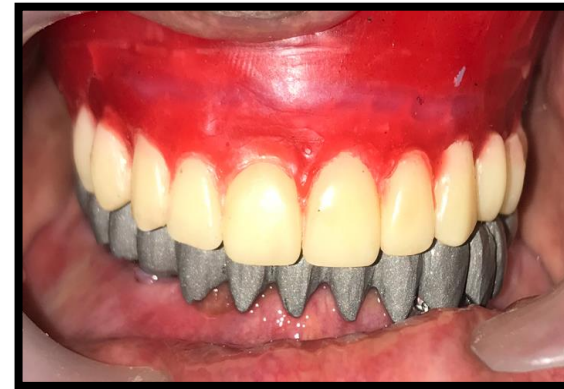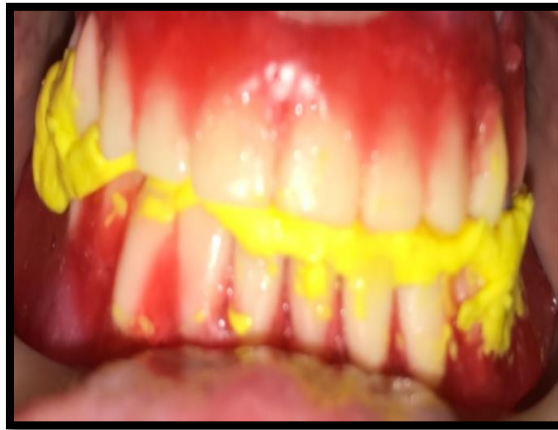**OPEN TRAY COPINGS PLACED**



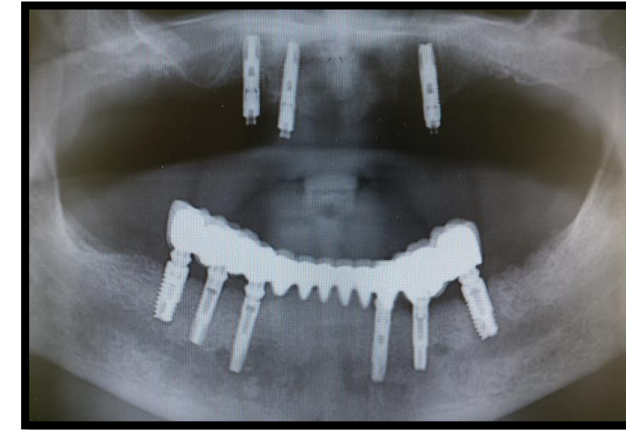
**MAXILLARY AND MANDIBULAR OPEN TRAY IMPRESSION MADE**



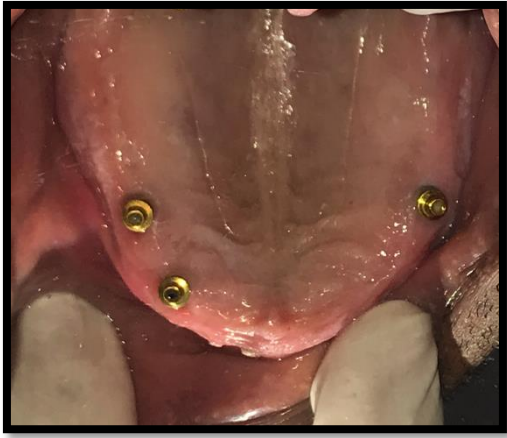**JAW RELATION DONE AND TRY IN DONE**



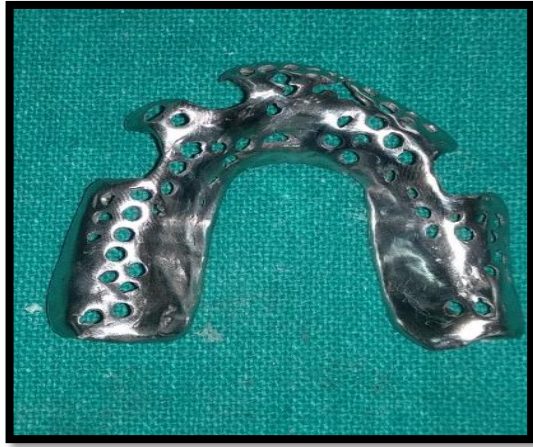**METAL TRY IN**



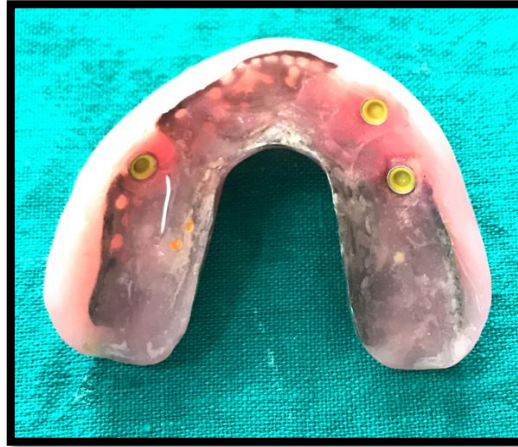**OPG SHOWING METAL TRY IN**



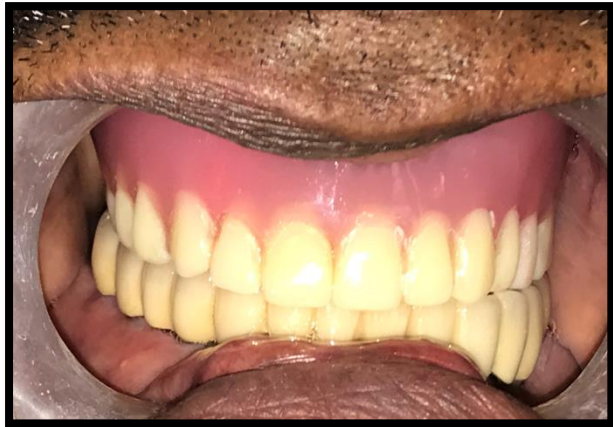
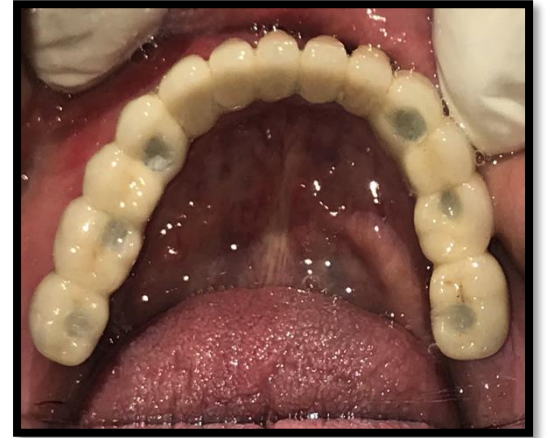**ALPHA LOCATOR PLACED  
WRT MAXILLARY ARCH**



**METAL FRAMEWORK DESIGNED  
AND CASTED FOR MAXILLARY ARCH**



**POST DENTURE INSERTION AND METAL  
CERAMIC BRIDGE CEMENTATION**



**POST OPERATIVE**