

Maxillary Overdenture

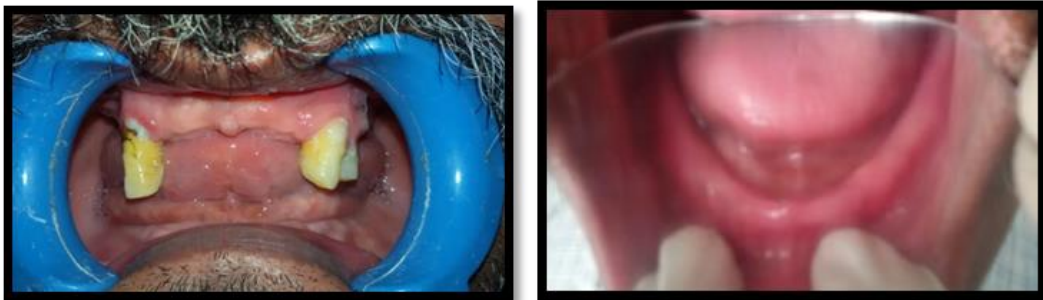Name-Chhatar Pal

Age-65 years

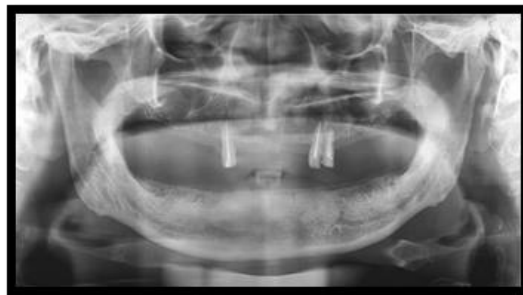
OPD No.- 20181011253

Chief complaint- Patient wants replacement of missing teeth.

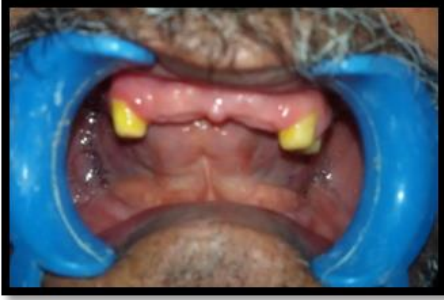Treatment by- Dr. Tanaya



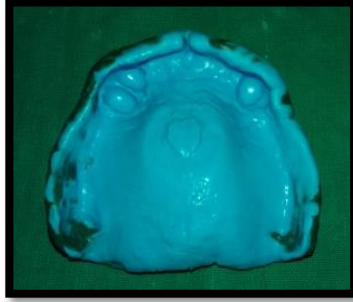
Pre operative



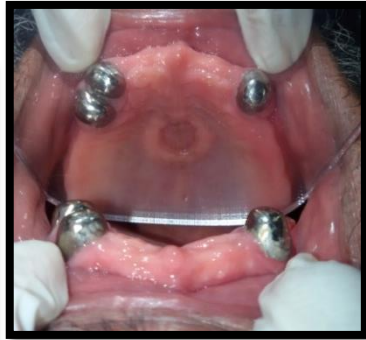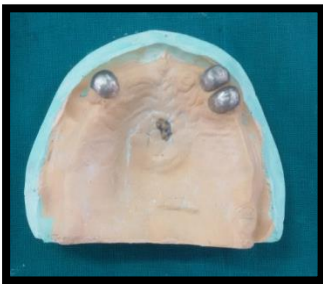Pre Operative OPG



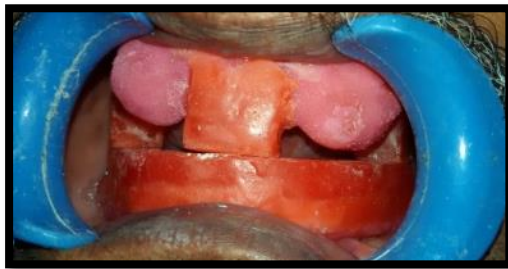After tooth preparation



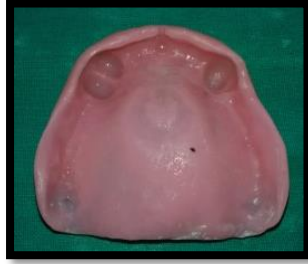Final impression



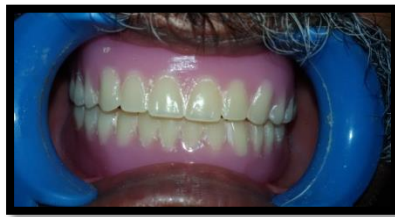Copings on cast
Copings in mouth



Jaw Relation



Maxillary denture showing the tissue surface



Post insertion