

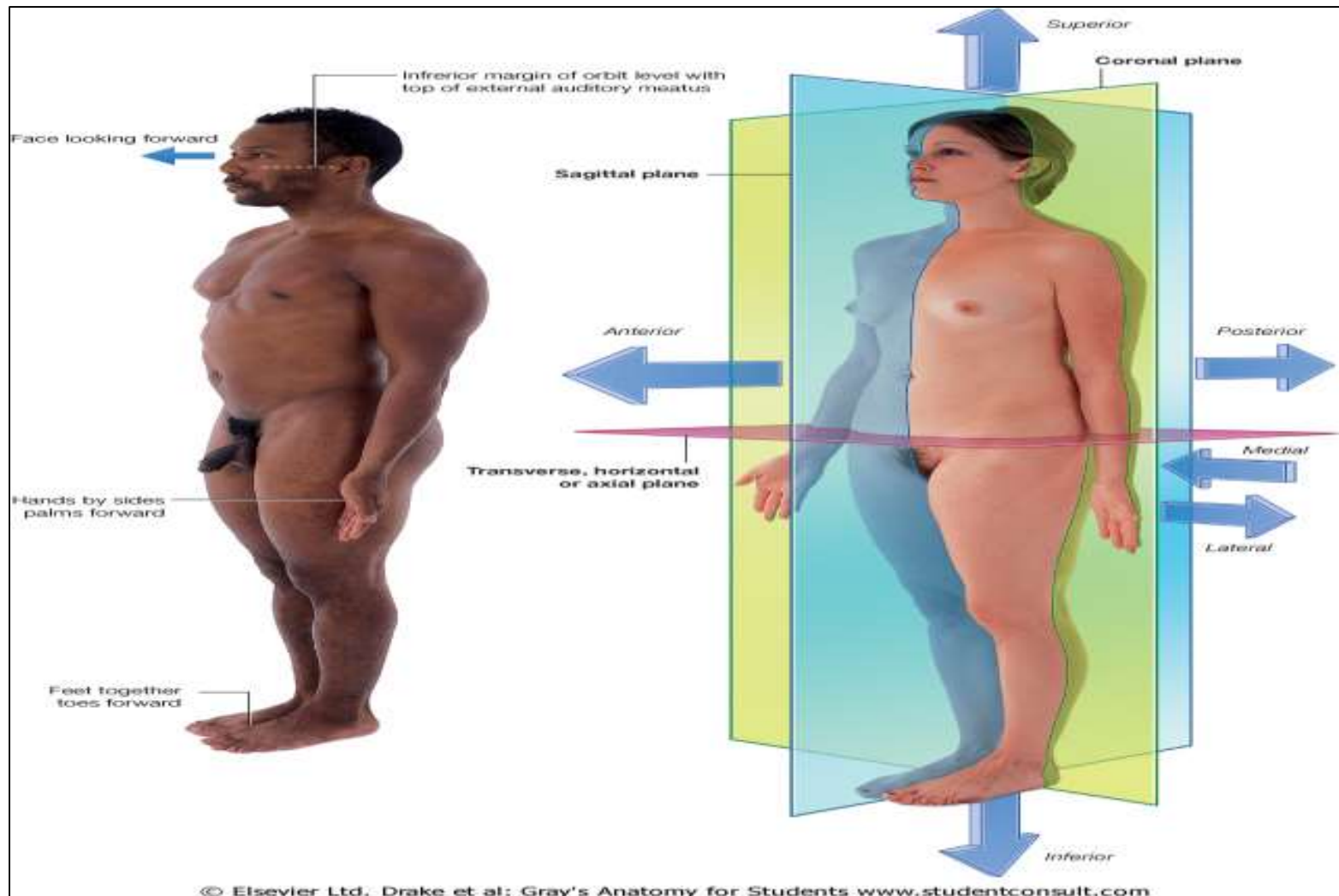
General anatomy 2

anatomical position and body planes

Anatomical position

all descriptions in the form of body refers to anatomical position of body where in:

- individual is standing upright
- With the upper limbs hanging by the sides
- And the palm of the hands directed forwards
- with head , eyes and toes directed forwards
- And the lower limbs are parallel with the toes pointing forwards.



supine position

- Lying down with face directed upwards

Prone position

- Lying down with the face directed downwards.

lithotomy position

- Lying supine with the buttocks at the edge of table
- Hips and knees fully flexed
- And the feet strapped in position

superior or cephalic (towards head)

- Position of a part that is nearest the head of a supposedly upright body .

inferior

- nearer the feet

Terms of relation

anterior-

- ventral or in front i.e nearest to front surface of the body.

posterior-

- dorsal or behind i.e nearer to back surface of body.

Medial

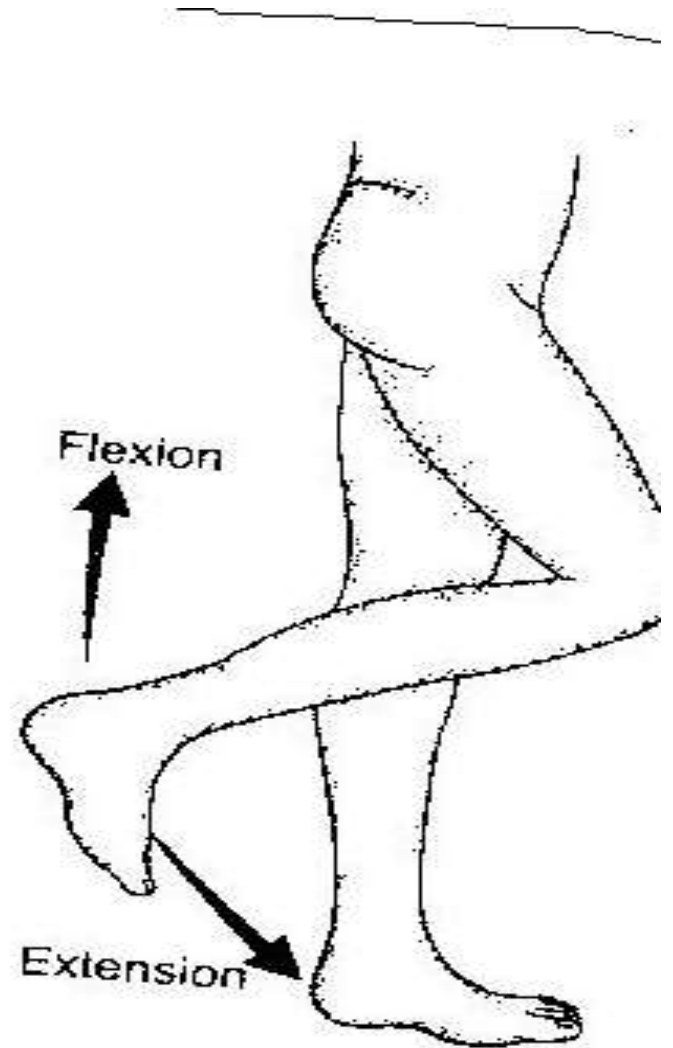
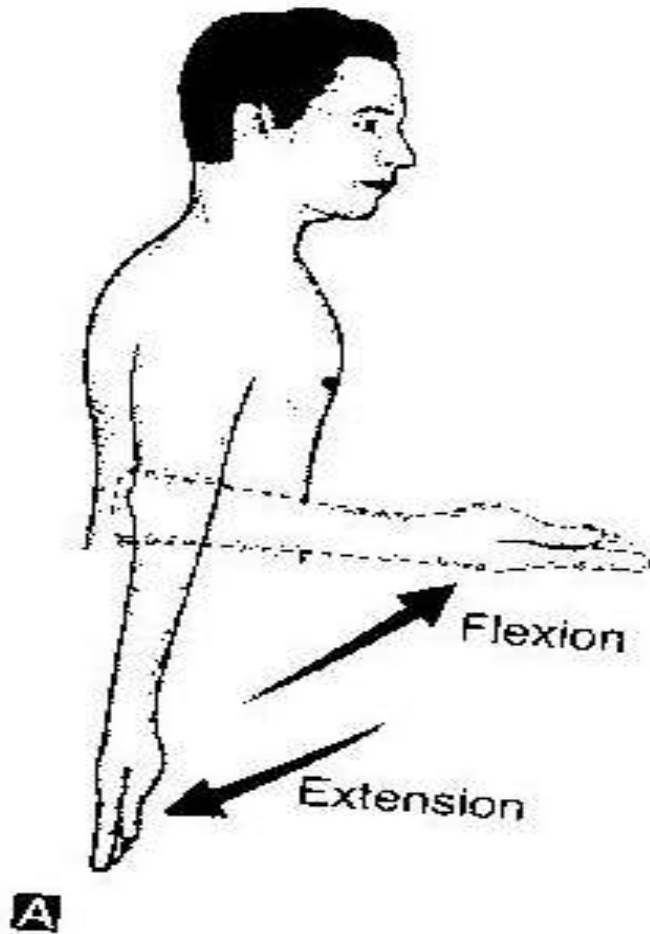
- Nearest to median plane of body

Lateral

- Away from median plane of body

Ventral and dorsal

- Used instead of anterior and posterior in the trunk.
- In hand dorsal ---- posterior ,palmer---- anterior.
- In foot superior surface of foot—dorsum of foot,
- inferior surface of foot ----planter .




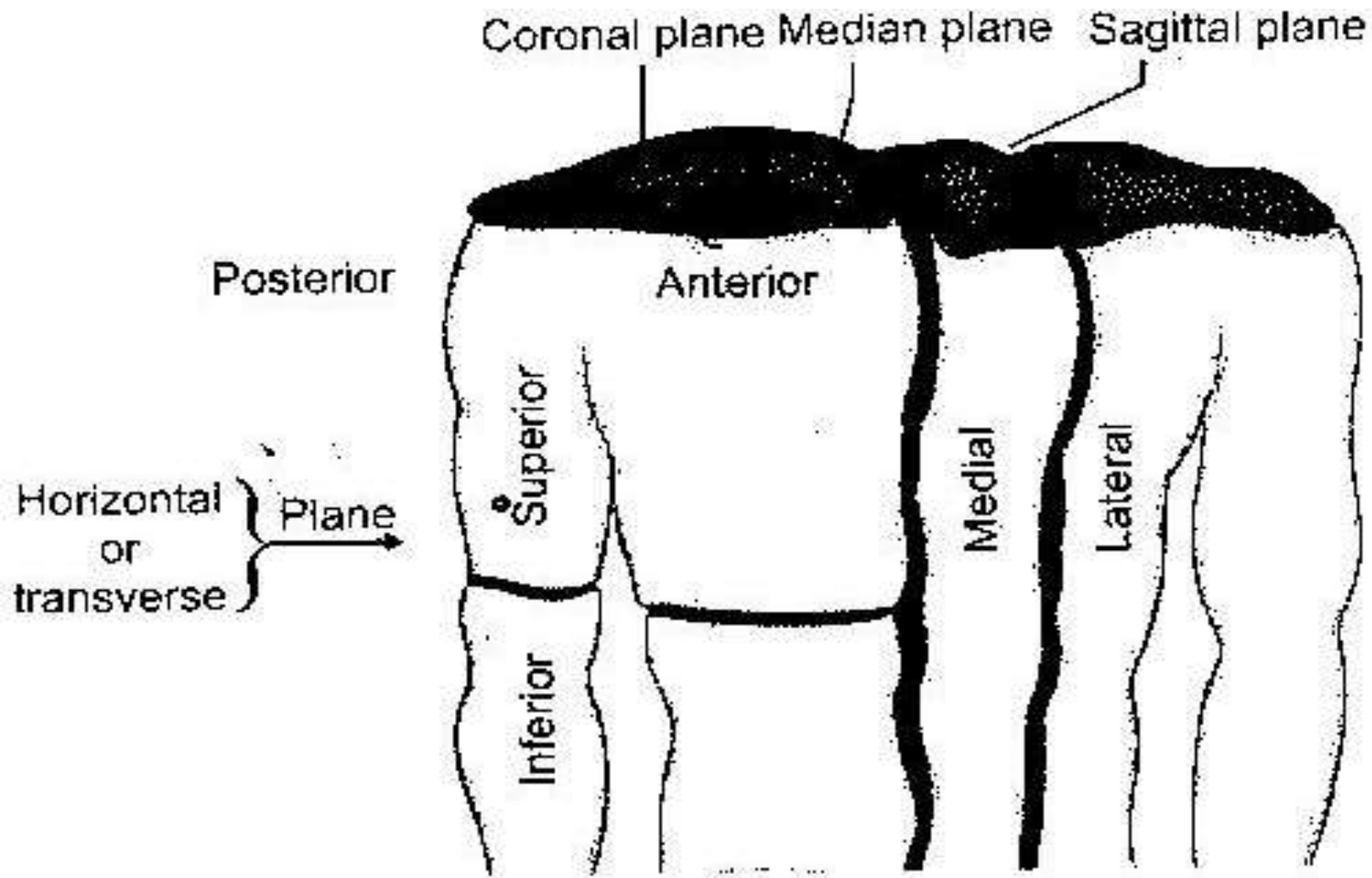


Fig. 1.6

Anatomical planes

- **median** or midsagittal plane;----divides into right and left halves.
- **Saggital** plane: plane parallel to median plane.
- **Coronal** plane : plane at right angle to median plane.
- **Transverse** plane :plane at right angles to a vertical plane.
- **Horizontal** plane :plane parallel to ground.
- **Oblique** plane :any plane other than the above said planes.



terms for limbs :

- proximal –nearer to trunk
- distal ----away from trunk
- Radial ----outer border of upper limb
- ulnar ---inner border of upper limb
- tibial --- inner border of lower limb
- fibular---outer border of lower limb.
- preaxial border—outer border of upperlimb,inner border of lower limb.
- postaxial border--

- flexor surface-
- extensor surface-
- palmer surface
- planter surface
- **terms used for hollow organs—**
- interior
- exterior
- Invagination or inward protrusion
- evagination or outer protrusion.

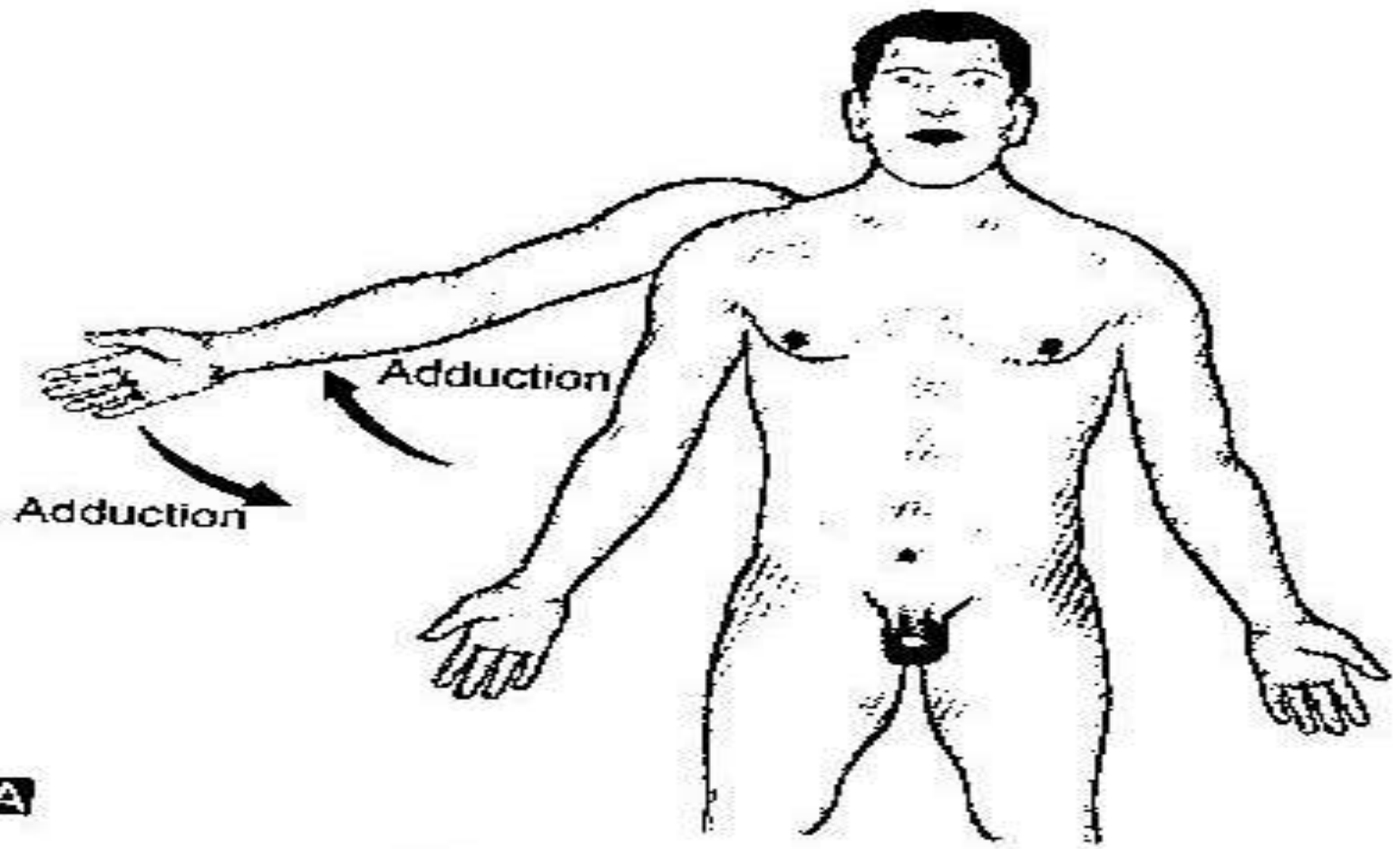
- **for solid organs-**
- superficial- towards surface
- deep--- inner to the surface.

terms to indicate side

- Ipsilateral---or same side
- contralateral---of opposite side.

Terms for movement

- **flexion**—approximation of flexor surfaces, whereby angle of joint is reduced. like dorsiflexion , planterflexion.
- **extension**---approximation of extensor surfaces, where angle of joint is increased.
- **adduction**---movement towards the central axis ,
- **abduction**– movement away from central axis i.e part is moving away from central plane.



A

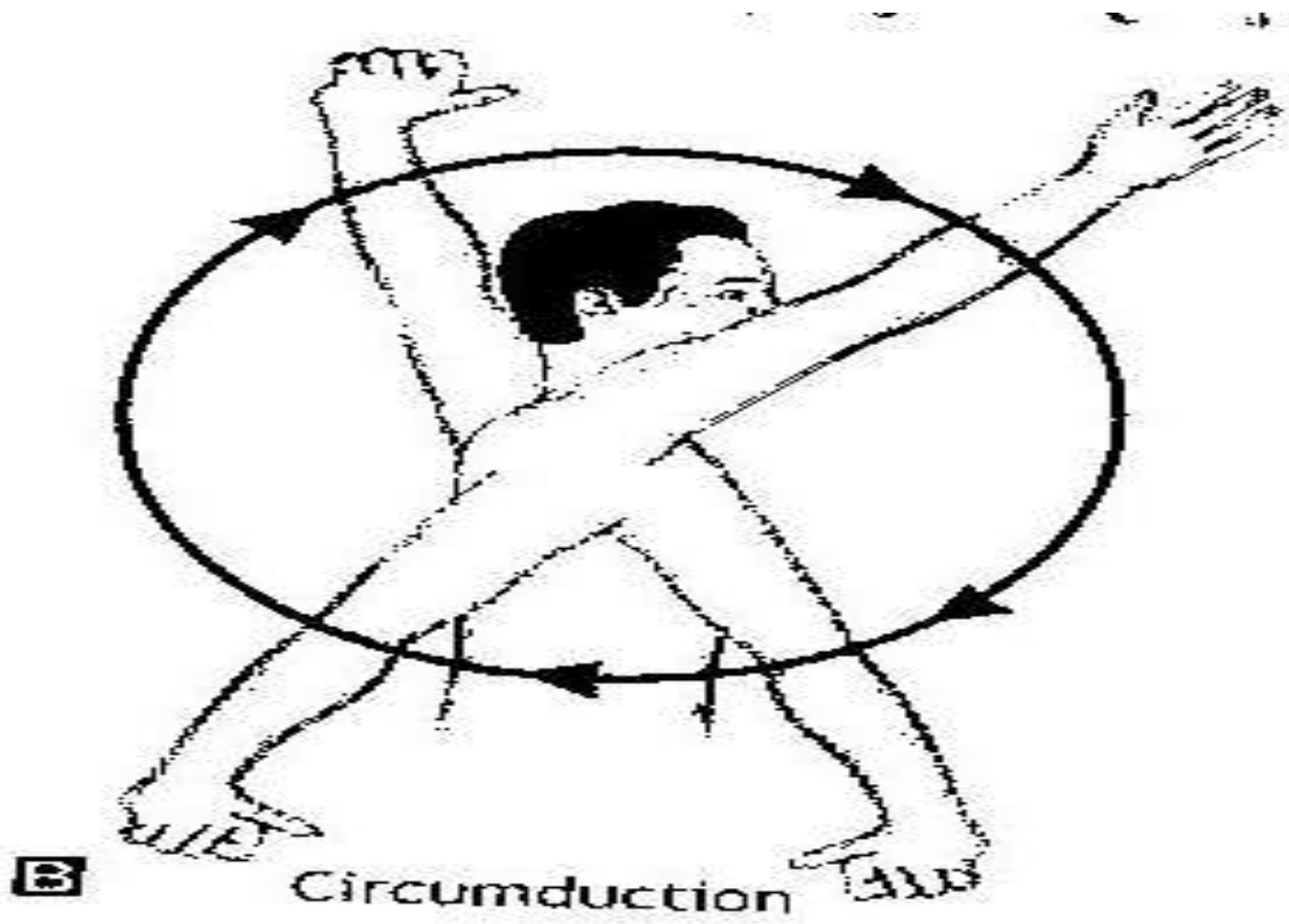


Fig 1.7

- medial rotation- inward rotation.
- lateral rotation – outward rotation
- circumduction- is all the above four movements in an order.
- pronation- rotation of forearm so palm is turned backwards .
- supination—
- protraction—forward protrusion
- retraction
- inversion' –sole of foot faces medially
- eversion.

mcq

1) A plane at right angle to a vertical plane is called---

- A) transverse plane
- B) coronal plane
- C) saggital plane
- D) horizontal plane

2) outer border of upper limb is called---

- A) post axial border
- B) preaxial border
- C) medial border
- D) none of above

3) Rotation of forearm so that the palm is turned forwards is as---

- a) pronation
- b) Supination
- c) protraction
- d) retraction

- Lying down position with face directed down is called as---
- A) supine position
- b) prone
- C) anatomical position
- d) lithotomy position